

Guided concept in the esthetic zone



A review of the surgical and prosthetic considerations

An article by Dr Stefen Koubi, Marseille/France and G rald Ubassy, Rochefort du Gard/France

In case of complex restorations in the anterior region, a precise and targeted therapy represents the preferred treatment option in order to achieve predictable and reproducible results.

Introduction

The restorative treatment of anterior teeth often presents a considerable challenge to general dentists. The aim is always to obtain the best possible result. A well-guided approach is necessary if the envisaged outcome is to be achieved. Precision planning and a consistent protocol are indispensable. Modern dentistry has simplified the ways and means of attaining esthetic results. Nevertheless, the success of the treatment, in the anterior region in particular, greatly depends on very careful planning, which includes a detailed analysis of the patient's smile as well as the fabrication of a working model. This model is used to plan and reproduce the shapes and contours of the future restoration with utmost precision. The present article describes a comparatively simple treatment technique on the basis of a clinical case. The initial esthetic

treatment plan was jointly developed by the dental technician and the dentist. It served as the guide or "GPS" for all the clinical steps, and it helped the dental team to successfully "navigate" through the treatment.

Clinical case presentation

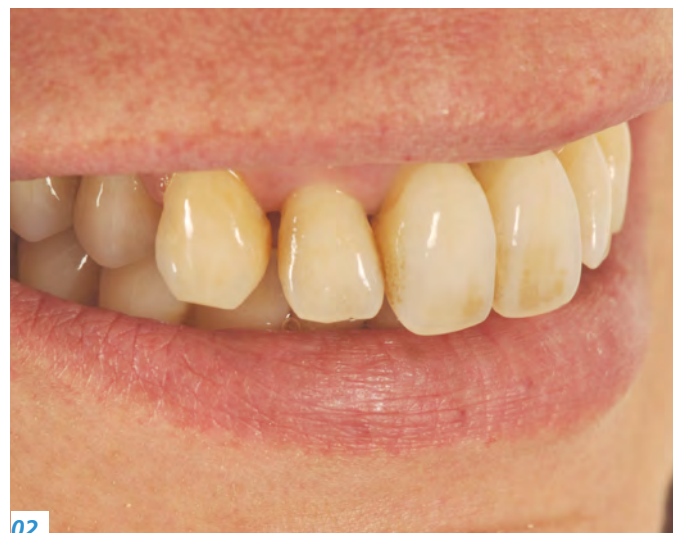A woman in her forties consulted our practice because of extremely mobile front teeth, which had caused esthetic problems (Figs 1 and 2). The teeth had moved forward and the level of the smile line had dropped. Due to severe periodontitis, the upper front teeth showed considerable gingival recession (Fig. 3). A detailed examination revealed that the four upper front teeth could not be saved and had to be extracted. The plan was to insert two implants in the sockets of tooth 12 and 22 after the extraction process. Subsequently,



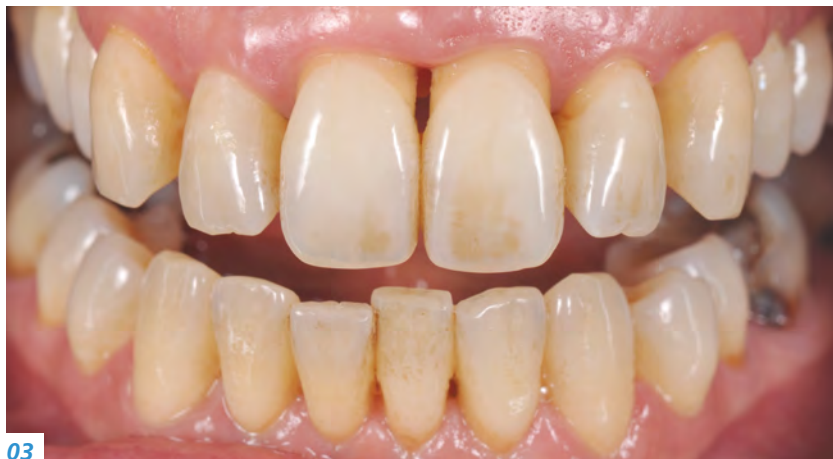01

01 — The patient was dissatisfied with her smile.

02 — The anterior teeth were damaged due to periodontitis and had moved forward.



02

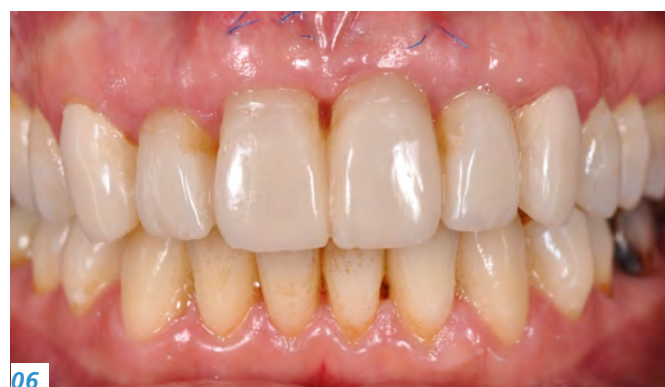
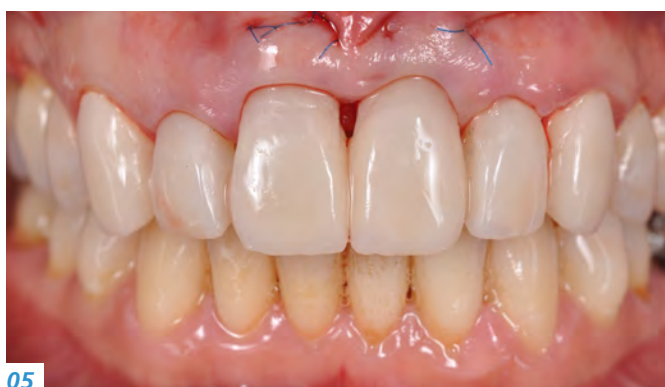
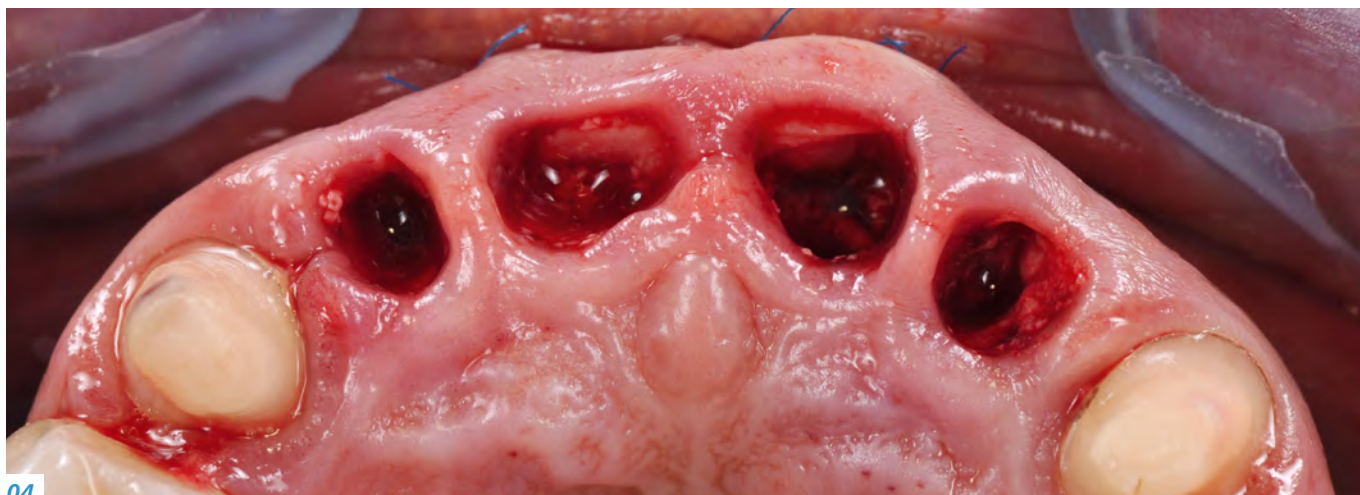03 — Intraoral view. Severe periodontitis had caused gingival recession on the two central incisors in the upper jaw.

04 — Situation after tooth extraction

05 — Placement of the provisionals during the implant insertion appointment

06 — Situation after six months



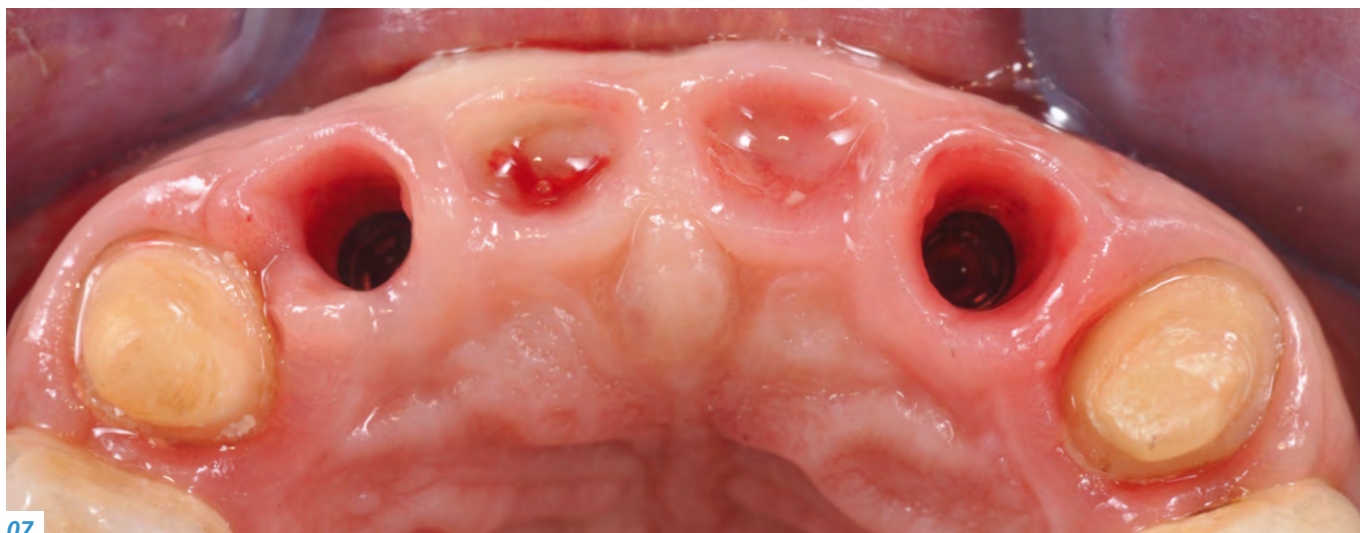
an implant-supported bridge extending from tooth 12 to 22 would be fabricated and tooth 13 and 23 would be restored with single crowns. The main objective was to restore the harmonious appearance of the smile line and the convex shape of the gingiva. The patient's smile was analyzed by means of a photographic record. Furthermore, impressions of the situation were taken. Based on this information, a provisional bridge spanning from tooth 13 to 23 and incorporating the esthetic and functional adjustments would be produced with PMMA material (Telio® CAD).

Surgical procedure

At the second treatment session, the four upper incisors were extracted. The canines 13 and 23 were prepared to receive the provisional bridge (Fig. 4). During the same ap-

pointment, two implants (V3, MIS Implants Technologies) were inserted in the sockets of tooth 12 and 22. They would serve as the abutments for the implant-supported bridge. The surgical procedure also included two connective tissue grafts in the area of tooth 11 and 21 in order to increase the horizontal volume of the jaw. The augmentation of the ridge tissue helped to restore the convex shape of the dental arch and established a sound basis for the development of a natural-looking emergence profile. Therefore, the alveolar sockets of tooth 11 and 21 were filled with a bone replacement material (xenograft product, Bio Oss) to prevent the gingival tissue from collapsing after the tooth extraction.

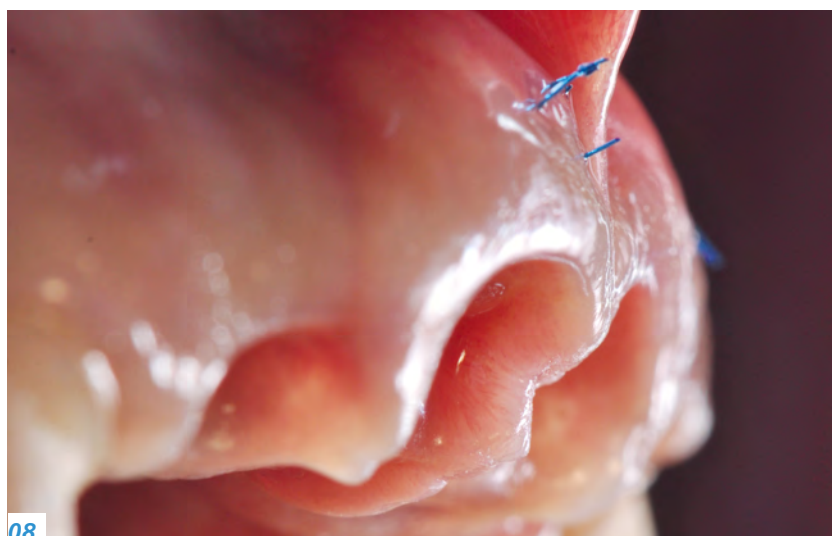After the surgical procedure, the provisional bridge was placed (Fig. 5). The provisional restoration plays a significant part in this type of treatment and considerably influences



07

07 — Occlusal view after the removal of the provisional restoration

08 — Excellent soft tissue conditioning. Due to the well-constructed provisionals, interdental papillae had formed successfully.



08

its outcome. A flowable composite material was applied to the base of the provisional bridge to condition the gingival tissue and shape the desired emergence profile. Suitable conditioning of the gums helps to preserve the tissue volume.

Note: When the model for the provisional restoration was fabricated in the dental laboratory, the alveolar sockets had to be prepared accordingly. Since this type of minimal surgical intervention prevented the need for flap surgery, the wound healed cleanly and quickly. Hardly any postoperative complaints occurred.

Six months later

The gingival conditioning measures showed to be successful when the provisional bridge was removed (Figs 6 and 7). Even the papillae between the upper tooth implants were

beautifully formed. This situation established an ideal basis for the smooth and esthetic integration of the permanent all-ceramic restorations (Fig. 8). Since bone resorption had progressed to an advanced stage in the anterior zone due to severe periodontitis, tilted implants had to be used: A screw-retained denture could not have been considered as a viable option in this case.

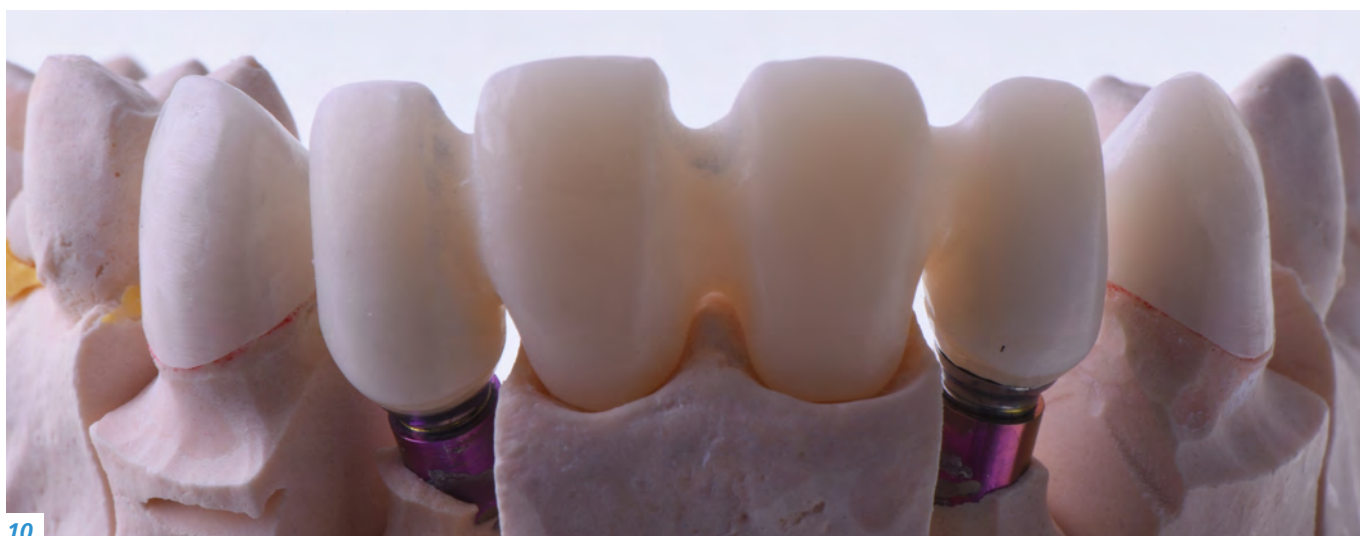Fabrication of the permanent restoration

After the final impression-taking process, a virtual model of the provisional restoration was produced. The frameworks were cut back to create a suitable basis for the ceramic restorations. The abutments were fabricated with IPS e.max® Press using the press technique. They were extraorally bonded to the titanium bonding bases with the reliable Multilink® Hybrid Abutment luting composite (Fig. 9). The zirconium oxide frameworks for the bridge as well as for the crowns on tooth 13 and 23 were produced with IPS e.max ZirCAD MT: a material featuring highly translucent and outstanding esthetic properties (Figs 10 and 11). The frameworks were characterized and individually veneered with the highly esthetic IPS e.max Ceram layering ceramic (Figs 12 and 13).



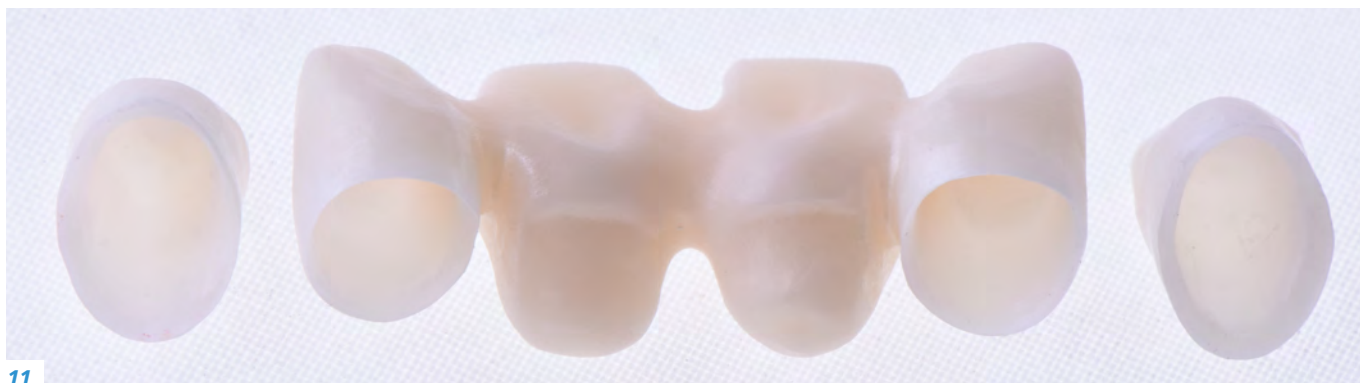09

09 — Hybrid abutments made with pressed ceramic (IPS e.max Press) on the model



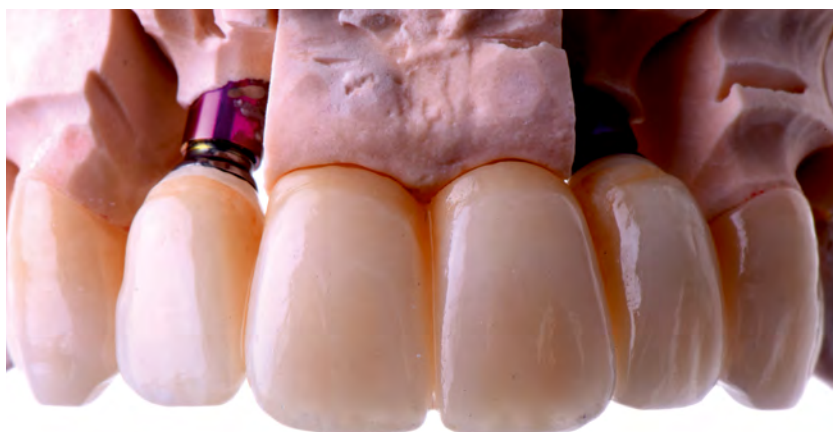10

10 — Crown copings and bridge framework made with IPS e.max ZirCAD MT (translucent zirconium oxide)



11

11 — Translucency of the zirconium oxide

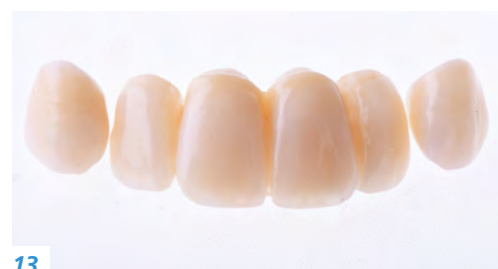

12

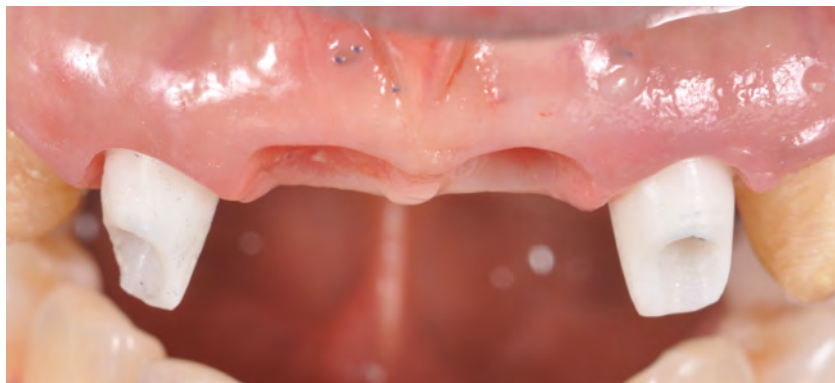
12 — Veneering of the framework with the IPSe.max Ceram layering ceramic

13

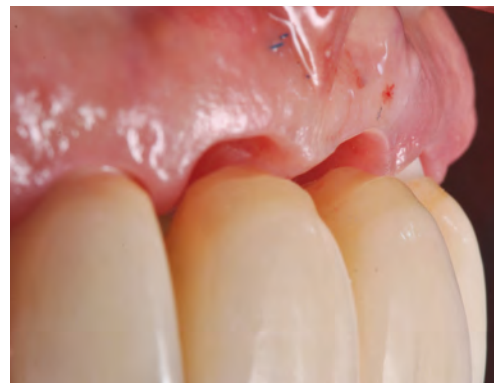13 — The restorations before placement



13



14 — *The all-ceramic abutments in situ*

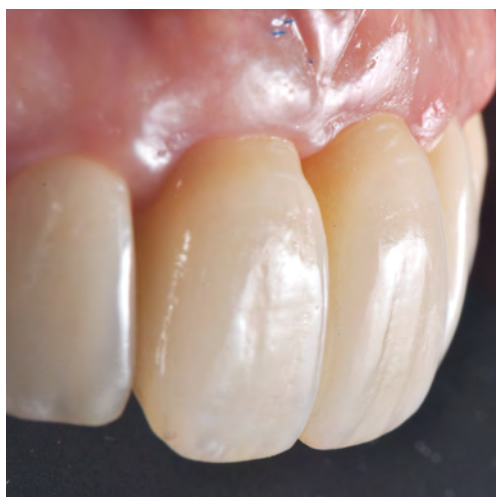

15 — *Integration of the bridge in the periodontium*

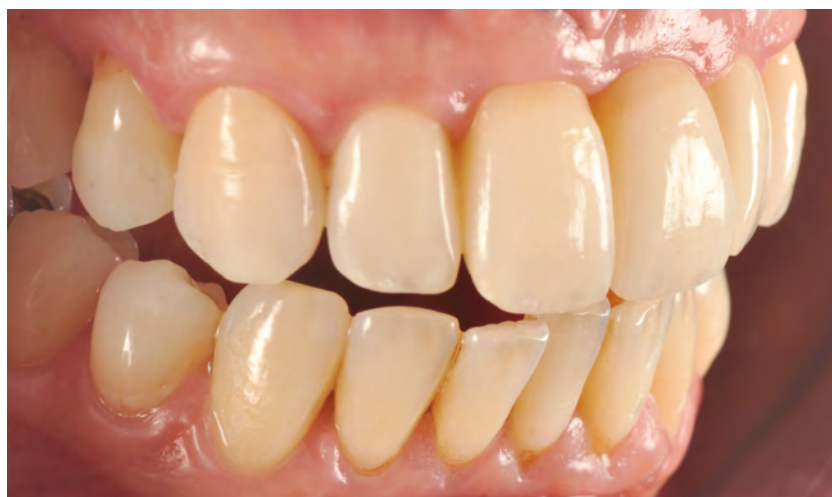Seating of the restorations

The try-in session again showed that the soft tissue was well-formed (Figs 14 and 15). The zirconium oxide-supported restorations were placed with the self-adhesive SpeedCEM® Plus luting cement. For this purpose, the IPS e.max

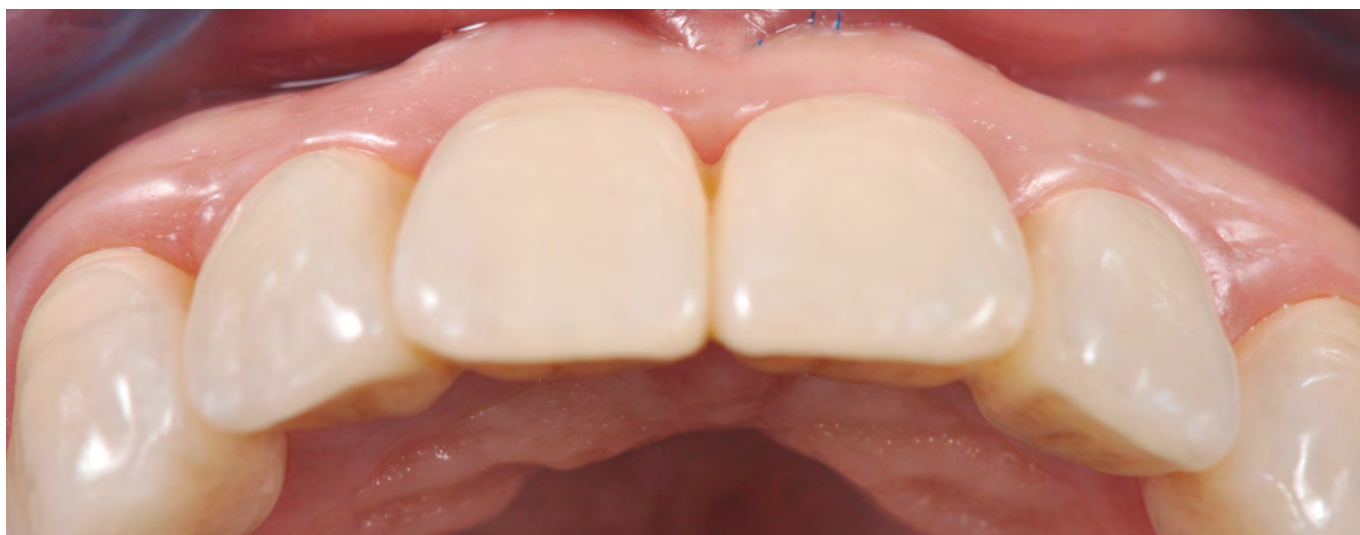Press lithium disilicate abutments were etched with hydrofluoric acid and then silanized with Monobond Plus in order to condition them for the bonding procedure to the bridge. The permanently seated zirconium oxide-supported crowns and the bridge exhibited a translucency level similar to that of lithium disilicate (Figs 16 to 18). The result in this case was exceptionally esthetic: The relationship between the restorations and the soft tissue looks harmonious and natural (Figs 19 to 21).



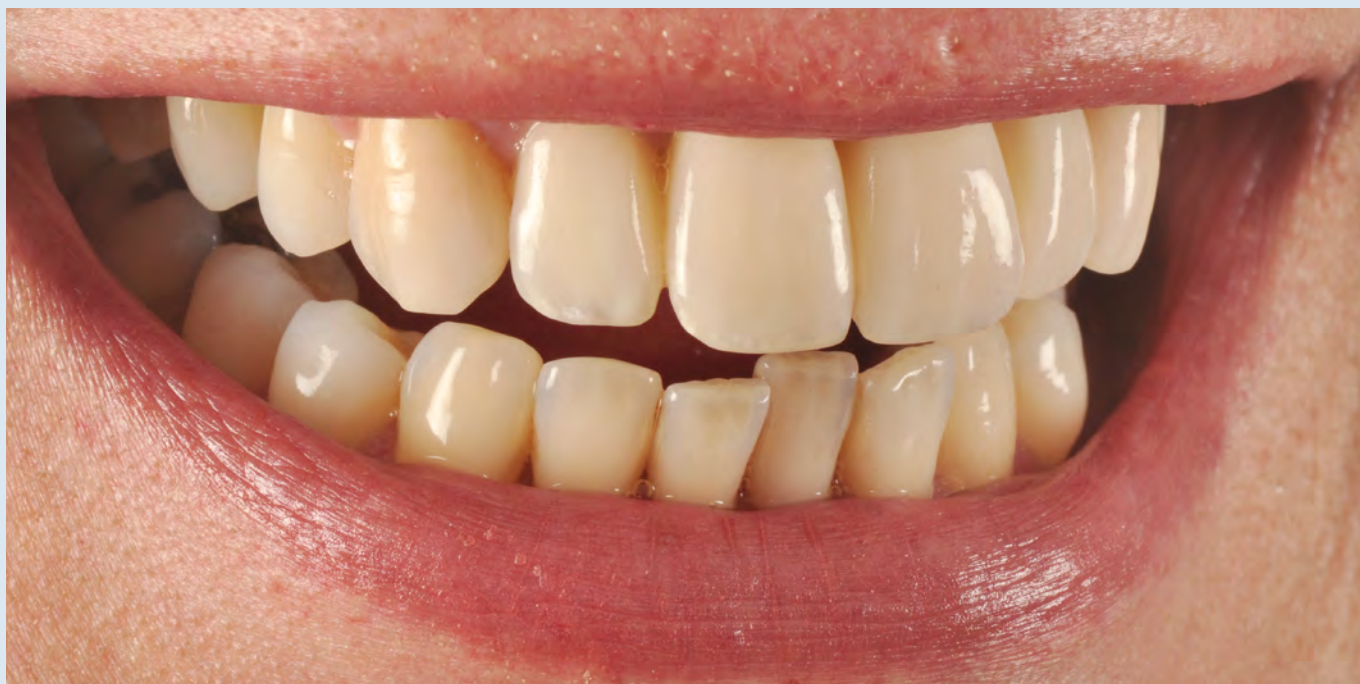16 — *Natural-looking emergence profile*



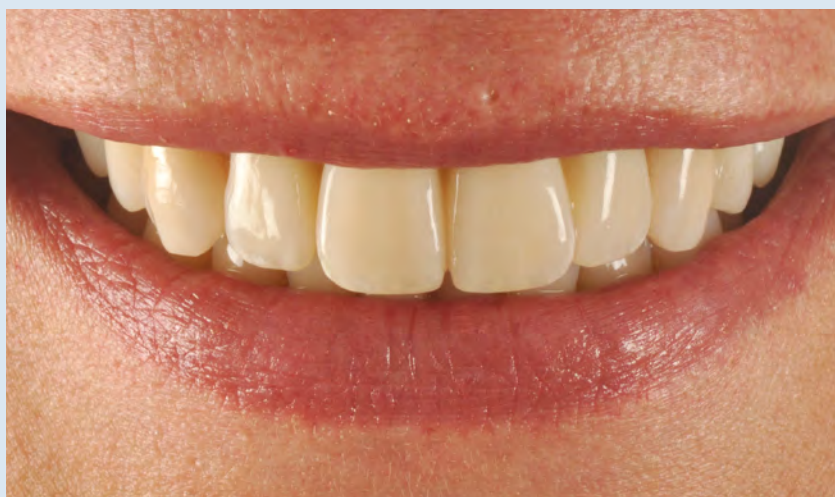17 — *Inspection of the functional parameters*



18 — *Occlusal view. The convex shape of the gingiva has been restored.*



19 — Close-up of the smile. Ideal light-optical properties



20 — Front view of the lip line with the patient smiling



21 — A happy patient

Conclusion

Precise planning and excellent collaboration among the members of the dental team are essential in the treatment of complex cases, since it is important to carry out the surgical interventions carefully and in stages. This immensely contributes to the final esthetic outcome. The ability to use translucent zirconium oxide in the anterior tooth region, due to the highly attractive optical properties of this material, opens up entirely new esthetic possibilities. In complex restorative procedures in the anterior zone, straightforward, well-planned and digitally based treatment protocols are the method of choice for obtaining predictable and reproducible results.



Dr Stefen Koubi
L'institut de la facette
51 bis, rue Saint Sébastien
13006 Marseille
France
koubi-dent@wanadoo.fr
www.linstitutdelafacette.com



G rald Ubassy
Centre de Formation International
Route de Tavel - Impasse des Ormeaux
30650 Rochefort du Gard
France
contact@ubassy.com
www.ubassy.com